

# Concentrated Albumin as a Biological Glue for Hemorrhage Control on Hepatic Resection with Argon Beam Coagulation

Hua Xie,<sup>1</sup> Ronald F. Wolf,<sup>1</sup> Allen P. Burke,<sup>2</sup> Scott B. Gustafson,<sup>3</sup> Kenton W. Gregory,<sup>1</sup> Scott A. Prah<sup>1</sup>

<sup>1</sup> Oregon Medical Laser Center, Providence St. Vincent Medical Center, 9205 SW Barnes Raod, Portland, Oregon 97225

<sup>2</sup> Armed Forces Institute of Pathology, 6825 16th St., Washington, DC 20306

<sup>3</sup> Oregon State University, College of Veterinary Medicine, 158 Magruder Hall, Corvallis, Oregon 97331

Received 9 September 2003; revised 5 February 2004; accepted 6 February 2004

Published online 14 May 2004 in Wiley InterScience (www.interscience.wiley.com). DOI: 10.1002/jbm.b.30077

**Abstract:** Topically applied concentrated albumin with argon beam coagulation (ABCA) has been shown to be more effective at achieving hemostasis than using argon beam coagulation alone (ABC) in a liver injury model. This study investigated the host response to the concentrated albumin after argon beam coagulation. Complete hemostasis was achieved using ABCA ( $N = 10$ ) or ABC ( $N = 10$ ) on a nonanatomic liver resection in a heparinized porcine model. The repairs were evaluated grossly and microscopically at postoperative periods of 30 and 90 days. We found no evidence of biliary leakage, rebleeding, or intraabdominal infection. Blood analysis indicated liver chemistry indices were within normal range after ABC and ABCA treatments. The histopathology showed that the postoperative healing response was similar in both groups: a moderate chronic inflammatory response as part of an on-going normal healing process. All repairs were encapsulated by fibrous tissue. There was no difference in the postsurgical adhesion scores for the ABCA (mean 3.4) and ABC (mean 3.8). It was concluded that use of the concentrated albumin as biological glue in conjunction with argon beam coagulation is a safe and efficient procedure for controlling hepatic hemorrhage in surgery. Further studies are warranted to investigate the clinical significance of this technique. © 2004 Wiley Periodicals, Inc. *J Biomed Mater Res Part B: Appl Biomater* 71B: 84–89, 2004

**Keywords:** hemostasis; liver; wound healing; *in vivo*

## INTRODUCTION

Surgery of solid visceral organs like liver, spleen, and kidney has always been challenging, not only in controlling hemorrhage, but also in preventing complications following surgery. Rapid, effective, and durable sealing of the injury site is the key to successful solid-tissue surgery. Traditional surgical techniques, such as gauze packing, mesh sutures, and staples, can fail to seal the resected surface immediately in patients with diffuse bleeding caused by hypothermia coagulopathy, extreme blood loss, electrolyte disturbance, or acidosis.<sup>1</sup> Fibrin glue can seal wound surfaces, but it performs poorly when bonding to a liver surface with active bleeding.<sup>2</sup> Thermal techniques have been used for hemorrhage control in surgery for many years by coagulating tissue and fusing small

vessels. The extracellular collagen in the coagulated tissue acts as a 'biologic glue' that bonds contiguous tissues.<sup>3</sup> The bond strength can be improved by adding exogenous protein before heating. This concept has been widely used in laser tissue welding in which albumin is used as a solder to join tissues.<sup>4</sup>

Our laboratory has successfully repaired serious hepatic injuries using a 52% concentrated albumin solder with an 810-nm diode laser.<sup>5</sup> Using this technique we have repaired severe hepatic trauma and nonanatomical hepatic resections with a free autologous omentum scaffold under Pringle's maneuver to achieve vascular control. However, the laser repair was time consuming for larger hepatic lesions, and required Pringle's maneuver to achieve temporary hemostasis.

The argon beam coagulator is frequently used in surgery for hemorrhage control of solid visceral organs.<sup>6–8</sup> A preliminary study tested whether adding a layer of concentrated albumin improved the efficiency of liver hemostasis when argon beam coagulation was used.<sup>9</sup> Our results showed that the average time to hemostasis in albumin group was significantly shorter than that needed in the group without adding

The opinions or assertions contained herein are the private views of the authors and are not to be construed as official or reflecting the views of the Department of the Army or the Department of Defense. No governmental endorsement should be inferred

Correspondence to: H. Xie (e-mail: hxie@providence.org)

Contact grant sponsor: Department of the Army; contract grant number: DAMD17-96-1-6006

Contract grant sponsor: The Providence St. Vincent Medical Foundation

© 2004 Wiley Periodicals, Inc.

albumin (mean 90 vs. 150 s,  $p = 0.001$ ). The albumin group was also less likely to require repeated argon beam coagulation (mean 0.5 vs. 1.5 times,  $p = 0.006$ ).<sup>9</sup>

Thermal denaturation has been reported to change the albumin alpha-helix molecular conformation to form a stable polymer with irreversible structural alteration.<sup>10</sup> This thermal denaturation could alter the biological characteristics of the albumin and cause immunologic or pathologic side effects. There is no data addressing the chronic effect of denatured albumin on hepatic wound healing after liver resection or repair. The current study investigated the safety of using the concentrated albumin with argon beam coagulation to control liver hemorrhage.

## MATERIAL AND METHODS

### Concentrated Albumin

Preparation of the concentrated albumin has been described previously.<sup>11</sup> Briefly, 25% human serum albumin (Michigan Department of Public Health, MI) from the hospital pharmacy was concentrated to 38% weight/volume using a pressure filtration chamber (Model 8400, YM 30 filter, Amicom, MA) under 35–45 psi at room temperature. The refractive index was measured to confirm the final concentration. The 38% albumin was drawn up into syringes, sterilized by gamma irradiation (30 kGy), and stored at 4°C until use.

### Surgery

Twenty juvenile domestic swine (body weight from 23–35 kg) were randomly divided into two groups to receive the treatment of argon beam coagulation alone (ABC) or argon beam coagulation with albumin (ABCA). Of the 10 animals in each group, 5 were euthanized at 30 and 90 days after surgery. All experiments were performed in accordance with the *1996 National Research Council Guide for the Care and Use of Laboratory Animals* and applicable federal regulations.

Domestic swine were numbered and correctly identified on the day of operation. Details of this animal model and surgical technique were described previously.<sup>9</sup> Briefly, the surgery was performed with the animals supine and under general anesthesia. Twenty minutes prior to operation, each animal was given 500 mg Cefotetan intravenously and blood samples were taken for preoperative lab studies that included a blood count, liver function tests, and activated clotting time (ACT). Vital indices, O<sub>2</sub> saturation and CO<sub>2</sub> tension were monitored during surgery. To create an anticoagulation model, 10 min prior to surgery, the animals were given 5000 units of heparin intravenously. A midline laparotomy was performed to expose the left medial liver lobe. A nonanatomic resection of the inferior aspect of this lobe was then performed. The resection was made approximately 8 cm from the tip of the lobe and created a 7 × 2 cm<sup>2</sup> raw parenchymal

surface. Animals randomly received either ABC or ABCA treatment for hemostasis. In the ABC group, the resection surface was treated using a standard argon beam coagulation process (Force Argon II, Valleylab, CO) with a setting of 75 Watts and 4 liters/min argon flow rate. In the ABCA group the resection surface was treated using the argon beam coagulator at the same settings but with the 38% human albumin applied to the raw parenchymal surface. In both groups, once initial hemostasis was achieved, the surface was packed with gauze for 3 min. If hemorrhage recurred, each animal received reapplication of ABC or ABCA as before until hemostasis was achieved. Once hemostasis was verified by visual inspection, the abdomen was closed without drains. The time needed to achieve hemostasis, the amount of blood loss, and the amount of albumin used were recorded.

After surgery the animals were monitored closely for signs and symptoms of liver failure and wound complications. Postoperative antibiotics were not administered. Blood laboratory indices, such as White Blood Cell Count (WBC), Hemoglobin (HGB), serum Glutamic-Oxalacetic Transaminase (AST), Glutamic-Pyruvic Transaminase (ALT), and Alkaline Phosphatase (ALK PHOS) were tested 4 days after surgery and on the day of sacrifice. The postsurgical adhesion score was evaluated by grossly examining the abdominal cavity,<sup>12</sup> and signs of infection were examined at the time of euthanization. The liver specimen was then harvested for histopathological examination.

Prior to sacrifice, the animals received either ABCA ( $N = 2$ ) or ABC ( $N = 3$ ) as described above. This procedure was done on the untreated left lateral lobe of the liver to obtain acute histopathological samples. Once hemostasis on this lobe was achieved, the animal was then sacrificed to harvest liver samples from the acute site and the chronic site of the original treated lobe.

### Histopathology

The specimen was placed in 10% buffered formalin for fixation. Tissue sections were stained with Movat pentachrome or Hematoxylin & Eosin.

### Statistics

All data are expressed as mean ± standard deviation. Parametric data of two groups was compared using an unpaired  $t$ -test. Pre- and postoperative data in the same group were examined by paired  $t$ -test. The Mann-Whitney  $U$ -test was used to analyze differences in numbers of adhesion scores.  $p$ -values < 0.05 were considered statistically significant.

## RESULTS

All animals tolerated surgery and steadily gained body weight after surgery without complications. In the ABCA group, an average of 3.5 ± 1.4 mL albumin was used (Table I).

**TABLE I. Variables of ABC and ABCA Treatments in Swine Model**

Variables	ABC	ABCA
Total No. of swine	10	10
No. of swine at 30-day period	5	5
No. of swine at 90-day period	5	5
Sex No. of M:F	7:3	5:5
Amount of Albumin use: mL · mean (range)		3.5 (1.2–6.8)
Body weight: kg · mean (range)		
Preoperative	30 (23–35)	30 (23–35)
At 30 days postop	44 (39–54)	43 (38–47)
At 90 days postop	98 (77–114)	109 (92–120)

Blood analysis showed that the indices of complete blood count and liver chemistry were in normal range (Table II). There was no difference in the number of white blood cells from preoperative and postoperative periods in the ABC and ABCA groups. Although statistical analysis showed that hemoglobin was lower at the day of sacrifice, the ALT was elevated postoperatively in both groups. The AST and alkaline phosphatase levels decreased after surgery in the ABCA group and the ABC group, respectively. These changes were still in normal range for swine. Furthermore, there were no observed external signs or symptoms related to these changes.

Gross examination of both groups showed that the cauterized tissue sealed the wounded surface acutely [Figure 1(A, B)]. Mild peritoneal adhesions were noted on the repaired liver surface at 30 and 90 days. There was no difference in the adhesion score between the ABC and ABCA treatments (mean 3.8 vs. 3.4,  $p = 0.9$ ).

Histopathologic studies showed similar changes in hepatic tissue after both treatments. Acutely, surface coagulation necrosis was observed with an underlying zone of hyperemic hepatocytes. The depth of tissue thermal injury was 2–3 mm in both groups [Figure 1(C, D)]. The treated area was coated

with a mixture of denatured albumin, red cells, and fibrin-platelet thrombus. This cauterized layer was approximately 2–3-mm thick in the ABCA treatment [Figure 1(D)] compared to 1-mm thick in the ABC treatment [Figure 1(C)]. The treated liver tissue showed hepatic cytolysis, vacuolation, and hyperemia caused by thermal heating [Figure 1(E, F)]. At day 30, a similar tissue reaction was seen in both treatments as the remnants of denatured albumin, necrosis hepatic tissue, and bile were surrounded by moderate inflammation. A small sterile abscess was formed around the degenerating inflammatory cells and degrading remnants, and was accompanied by a granulomatous reaction [Figure 2(A–D)]. The repaired sites were encapsulated by fibrous tissue with focal ossification, which was related to chronic inflammatory reaction after surgery [Figure 2(A)]. Hepatic cell degeneration and regeneration coexisted with adjacent inflammation in the liver parenchyma [Figure 2(E, F)]. In most ABCA treatments, moderate inflammation was noted in response to residual denatured albumin and necrotic tissue.

## DISCUSSION

Clinical observation and laboratory tests indicated that all animals were healthy without local or systemic complications. Both groups exhibited similar histopathological changes: cauterized liver mixed with denatured albumin, cell debris, and fibrin thrombus to form a seal on the liver surface. In the ABCA group this layer seemed to be thicker and more homogeneous due to the added albumin. We believe that this coagulated albumin layer provides a substantial foundation to improve the efficacy of argon ion beam coagulation in liver hemorrhage control.

The only difference noted between the two groups was that in the ABCA group a small amount of residual albumin was still present at 90 days. The ABCA treatment used an average of 3.5 mL of concentrated albumin, and so the

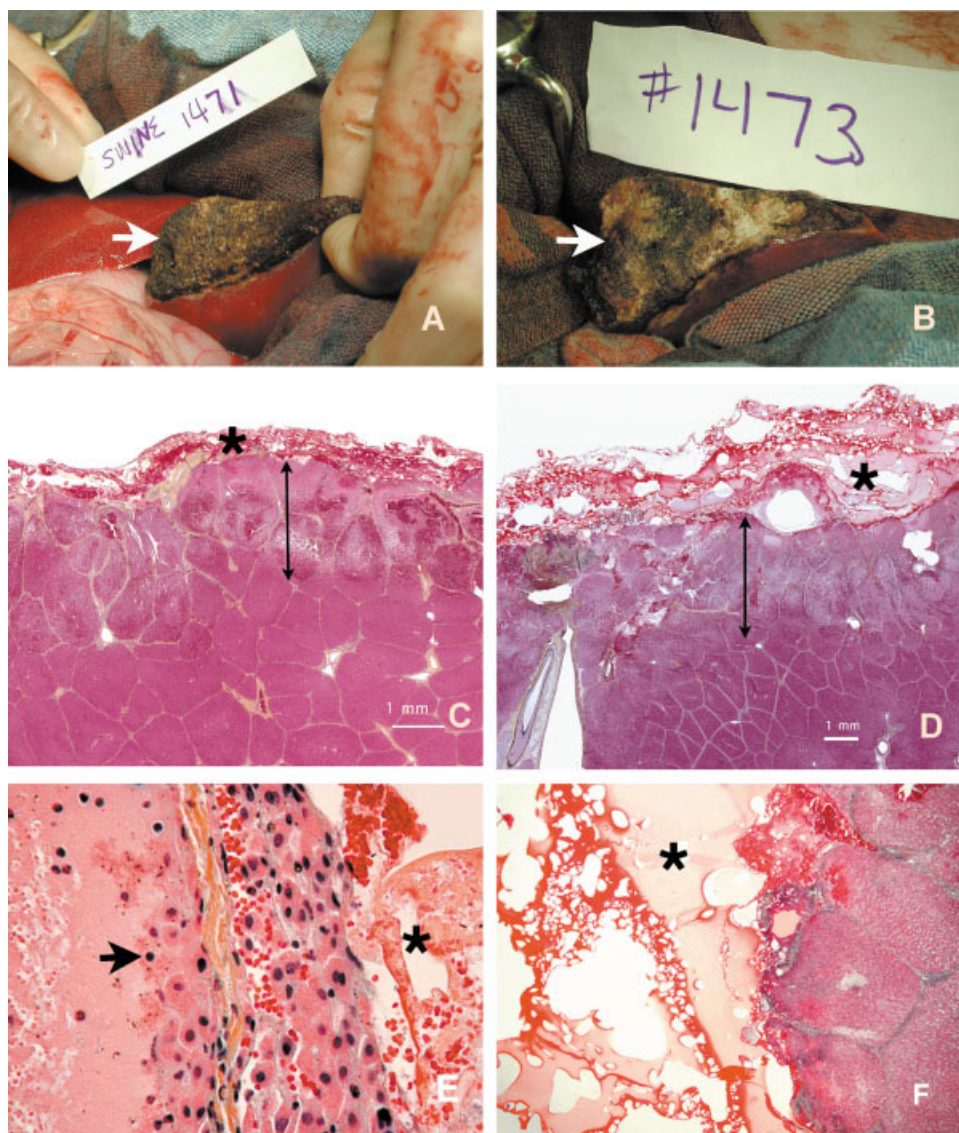
**TABLE II. Comparison of White Blood Cell Count (WBC), Hemoglobin (HGB), serum Glutamic-Oxalacetic Transaminase (AST), Glutamic-Pyruvic Transaminase (ALT), and Alkaline Phosphatase (ALK PHOS) of ABC and ABCA Treatment (Average ± SD)**

Variables Normal Range (Unit)	Group	Preop	Day 4 Postop	Day of Sacrifice
WBC (1000/UL)	ABC	18.7 ± 4.1	16.9 ± 6.2	14.9 ± 4.3
	ABCA	20.6 ± 4.4	18.9 ± 4.0	16.1 ± 3.0
HGB (G/DL)	ABC	10.7 ± 0.7	10.0 ± 2.6	9.9 ± 0.9 <sup>b</sup>
	ABCA	10.5 ± 0.8	10.6 ± 1.1	9.6 ± 0.9 <sup>b</sup>
AST (IU/DL)	ABC	49 ± 17	52 ± 11	44 ± 13
	ABCA	48 ± 16	49 ± 17	41 ± 22 <sup>b</sup>
ALT (IU/DL)	ABC	29 ± 11	43 ± 18 <sup>*</sup>	41 ± 12 <sup>b</sup>
	ABCA	27 ± 6	33 ± 15	35 ± 6 <sup>b</sup>
ALK PHOS (IU/L)	ABC	172 ± 45	128 ± 46 <sup>a</sup>	129 ± 21 <sup>b</sup>
	ABCA	140 ± 44	140 ± 36	125 ± 29

The normal range from ANTECH Diagnostics.

<sup>a</sup>Significantly different from preop value versus day 4 postop value.

<sup>b</sup>Significantly different from preop value versus day of sacrifice.



**Figure 1.** Hemostasis after partial hepatectomy using ABC and ABCA. (A,B) A layer of cauterized tissue sealed the liver resection surface (arrow) in both ABC (A) and ABCA (B) treatments. (C,D) A 2–3-mm depth of thermal injury is seen in hepatic parenchyma (between double arrow) in the ABC (C, Movat stain,  $\times 8$ ) and the ABCA (D, Movat stain,  $\times 4$ ) treatment. A layer of cauterized material, including denatured albumin, plasma and necrotic tissue (star) is 1 mm thick in the ABC treatment and 2–3 mm thick in the ABCA treatment. (E) The thermal tissue injury resulted in hepatic cytolysis (arrow), vacuolation, and hyperemia in both treatments (Movat stain,  $\times 400$ ). (F) In ABCA treatment, a homogeneous layer of the coagulated albumin (star) is found on the liver surface (Movat stain,  $\times 100$ ). [Color figure can be viewed in the online issue, which is available at [www.interscience.wiley.com](http://www.interscience.wiley.com).]

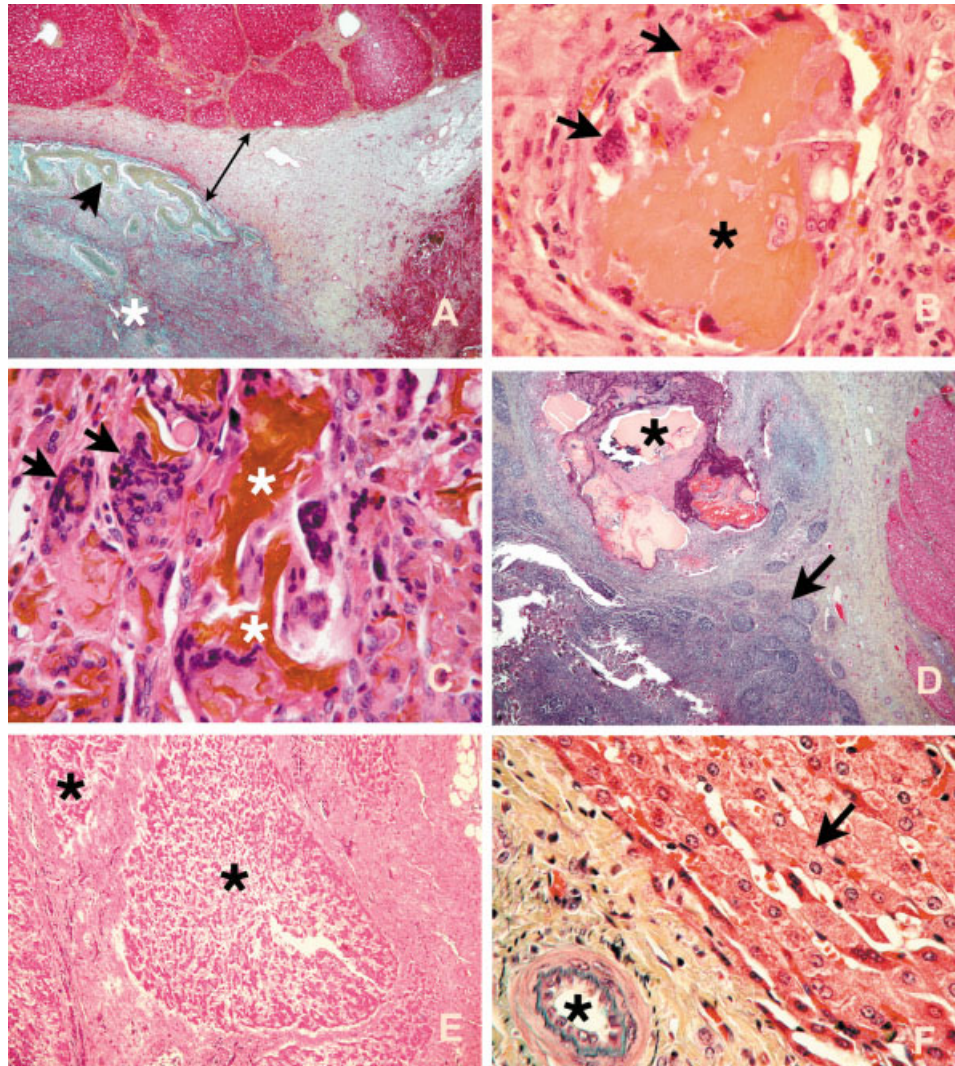
healing process in the ABCA group needed to degrade more material than the ABC group. Consequently, it was not surprising that some residual albumin still remained at 90 days. In general, our results indicate that the inflammatory response is a benign, long-term process that depends on the size of the repair and the amount of albumin applied. Finally, it should be mentioned that the use of human albumin may have induced an immunogenic response in the porcine model.

The albumin concentration can be varied for different applications and applicators. Our laboratory found that approximately 52% albumin was optimal for laser assisted

hepatic injury repair<sup>5</sup> and the 38% albumin was selected for ABC hepatic applications.<sup>11</sup> The histopathological results are comparable in the ABC and in the laser study.<sup>5</sup> This technique can be utilized for hemorrhage control in varying surgical procedures, such as tumor resection, trauma repair, as well as for surgery on other solid organs.

In conclusion, adding concentrated albumin in association with argon beam coagulation is a safe and efficient procedure for hemorrhage control. Using ABCA may potentially reduce the morbidity and mortality of related to rehemorrhage or bile leakage in hepatic surgery.





**Figure 2.** Hemostasis after partial hepatectomy using ABC and ABCA at 30 and 90 days postoperatively. (A) A sterile abscess (star) containing remnants of denatured albumin, necrotic tissue, and bile. The abscess is encapsulated by fibrous tissue (between double arrow) with focal ossification (arrow head) at 30 days in an ABC treatment (Movat stain,  $\times 25$ ). (B) Foreign body reaction to necrotic hepatic tissue (star) with several giant cells (arrows) at 30 days in the ABCA treatment (Movat stain,  $\times 400$ ). (C) Remnants of denatured albumin and bile (stars). Giant cells (arrows) dominate foreign body reaction at 30 days in the ABC treatment (H&E stain,  $\times 400$ ). (D) Inflammatory response to necrotic tissue, denatured albumin, and bile remnants (star) with granulomatous reaction and chronic lymphoid aggregation at 30 days in ABCA treatment (H&E stain,  $\times 25$ ). (E) Degenerated hepatic lobular aggregation are replaced by fibrous tissue at 90 days (H&E stain,  $\times 100$ ). (F) Hepatic cells regeneration (arrow) with neovascularization (star) at 90 days (Movat,  $\times 400$ ). [Color figure can be viewed in the online issue, which is available at [www.interscience.wiley.com](http://www.interscience.wiley.com).]

The authors would like to express appreciation to Katie Lublink, Lori Gibson, DVM, Monika Masuda, and Victoria Feldmann for their surgical assistance, and to Ted Moffitt for the albumin preparation.

## REFERENCES

1. Longmire WP, Tompkins RK. Hepatic trauma. Manual of liver surgery. Berlin: Springer-Verlag; 1981. p 157–179.
2. Jessen C, Sharma P. Use of fibrin glue in thoracic surgery. *Ann Thorac Surg* 1985;39:521–524.
3. Murray L, Su L, Kopchok GE. Crosslinking of extracellular matrix proteins: A preliminary report on possible mechanism of argon laser welding. *Lasers Surg Med* 1989;9:190–196.
4. Bass LS, Treat MR. Laser tissue welding: A comprehensive review of current and future clinical applications. *Lasers Surg Med* 1995;17:315–349.
5. Wadia Y, Xie H, Kajitani M. Sutureless liver repair and hemorrhage control using laser-mediated fusion of human albumin as a solder. *J Trauma* 2001;51:51–59.
6. Papadimitriou JD, Fotopoulos AC, Prahalias AA, Vassiliou JG, Papadimitriou LJ. The impact of new technology

- on hepatic resection for malignancy. *Arch Surg.* 2001;136:1307–1313.
7. Kwon AH, Inui H, Kamiyama Y. Successful laparoscopic homeostasis using an argon beam coagulator for blunt traumatic splenic injury. *Eur J Surg.* 2001;167:316–318.
  8. Pilitsis JG, Brisson PA. The use of argon beam coagulation in the management of bleeding from an ulcerated breast lesion. *Breast J* 1999;5:269–271.
  9. Wolf RF, Xie H, Petty J, Teach JS, Prah SA. Argon Ion beam hemostasis with albumin following live resection. *Am J Surg.* 2002;183L584–587.
  10. Horton HR, Moran LA, Ochs RS, Rawn JD, Scrimgeour KG. Protein denaturation and renaturation. *Principles of biochemistry*, 2nd ed. Englewood Cliffs, NJ: Prentice Hall; 1996. p 101–103.
  11. Moffitt TP, Baker DA, Kirkpatrick SJ, Prah SA. Mechanical properties of coagulated albumin and failure mechanism of liver repaired using argon beam coagulator with albumin. *J Biomed Mater Res* 2002;63:722–728.
  12. Shimanuki T, Nishimura k, Montz FJ, Nakamuura RM, diZerega GS. Localized prevention of postsurgical adhesion formation and reformation with oxidized regenerated cellulose. *J Biomed Mater Res* 1987;21:173–185.